



Morpho-histological Study of the Rat Spleen Post-Induction of Sodium Nitrite and *Acorus calamus* L. Rhizome Ethanolic Extract

Siti Amira^{1*}, Husnarika Febriani¹, Syukriah¹, Ulinnuha Nur Faizah²

¹Departement of Biology, Faculty of Sains and Technology, Universitas Islam Negeri Sumatera Utara, Medan, Indonesia

²Department of Natural Science, Faculty of Education and Teaching Science, Institut Agama Islam Negeri Ponorogo, Ponorogo, Indonesia

* Corresponding author

e-mail: sitiamira522@gmail.com

Article History

Received : 23 June 2023
Revised : 10 August 2023
Accepted : 5 September 2023
Published : 30 September 2023

Keywords

Bleeding, histomorfometry, nitrosamine, sweetflag, white Pulp

ABSTRACT

Sodium nitrite (NaNO_2) is one of the most inorganic salts and is often used in processed meat products. Long-term consumption of sodium nitrite has been reported to cause of oxidative stress and spleen histological changes. Therefore, anti-oxidative effects are needed from natural ingredients such as *Acorus calamus* L. The study aims to determine the effect of *A. calamus* L. rhizome extract on anatomical structure and histological changes in the rat spleen induced with NaNO_2 . We used a completely randomized design with twenty-five male rats divided into 5 groups. Negative control (NC) was given 0.5% CMC for 40 days; positive control (PC) on days 1-15 was given NaNO_2 (50 mg/kg BW); on days 16-30 given (50 mg/kg BW) NaNO_2 + 0.5% CMC and on days 31-40 given 0.5% carboxy methyl cellulose (CMC). Treatment 1 (T1), Treatment 2 (T2), and Treatment 3 (T3) on days 1-15 were given NaNO_2 doses of 50 mg; and; on days 16-30, groups T1, T2, and T3 were given NaNO_2 + extract with each predetermined dose (250 mg/kg BW for T1, 500 mg/kg BW for T2, and 750 mg/kg BW for T3). For days 31-40 groups T1, T2, and T3 were given extracts with each predetermined dose. Results revealed that the extract of the *A. calamus* L. rhizome affects weight, length, and width of the spleen ($P < 0.05$); and bleeding lesions; while having no noticeable effect ($P < 0.05$) and having a noticeable effect on the area of the white pulp ($P < 0.05$). Administration of ethanol extract of *A. calamus* L. at a dose of 250 mg/kg BW has an impact on improving spleen weight and width; a dose of 500 mg/kg BW has an impact on the weight and length of the spleen; and a dose of 750 mg / kg BW has an impact on improving spleen width length, but the size variation is still in the normal category. While extracts at doses of 250 and 500 mg/kg BW have a repair impact on tissue shrinkage in damaged white pulp.

How to cite: Amira, S., Febriani, H., Syukriah., & Faizah, U.N. (2023). Morpho-histological Study of The Rat Spleen Post-Induction of Sodium Nitrite and *Acorus calamus* L. Rhizome Ethanolic Extract. *Jurnal Riset Biologi dan Aplikasinya*, 5(2):89-97. DOI: [10.26740/jrba.v5n2.p.89-97](https://doi.org/10.26740/jrba.v5n2.p.89-97)

INTRODUCTION

Sodium nitrite (NaNO_2) is one of the food additives that is commonly used to preserve meat products such as sausages, corned beef, ham, etc. Sodium nitrite can also add and retain a red color in meat because nitrite can decompose into nitroxides that can react to myoglobin present in meat so that nitroso myoglobin is formed (Sindelar & Milkowski., 2012; Karwowska et al., 2021). According to The Council and Commission of the European Union (EU) Regulation No.1129/2011 on food additives, sodium nitrite levels are allowed for use in meat products that are 150 mg/kg (Wójciak

et al., 2019). Although there is already a safe dose for sodium nitrite, some products still contain sodium nitrite that exceeds the recommended limits. World Health Organization (WHO) suggests an Acceptable Daily Intake (ADI) of sodium nitrite that can be accepted by the body at about 0.06-0.07 mg/kg of body weight (Ma et al., 2018).

Long-term consumption of sodium nitrite may have a bad effect on health such as histological changes in the spleen (Suparmi et al., 2016). This can happen if nitrites enter the body and react with amine compounds to form a new compound called nitrosamine. Nitrosamine compounds can activate

and increase the production of Reactive Oxygen Species (ROS) so they can potentially be carcinogens (Suttie, 2006; Sindelar & Milkowski, 2012; Mohammed, 2014). Consumption of sodium nitrite causes damage to blood vessels, the liver, the spleen, and other organs in rats (Juibar et al., 2015; Petrova et al., 2020; Sanjari & Hosseini, 2021).

Spleen is one of the organs that plays an important role in the immune system and hematopoiesis processes. The process of hematopoiesis in the spleen occurs in fetuses aged 2-7 months; after that, the spinal cord takes over the hematopoiesis process in fetuses aged 7 months to adulthood (Turk et al., 2009). The process of hematopoiesis in the spleen will reappear when a person experiences methemoglobinemia and spontaneous hemolysis by erythrocytes in vivo in the human body due to the influence of toxicity agents (Suttie, 2006). Therefore, anti-oxidative and anti-inflammatory from secondary metabolites are needed that can prevent and reduce the effects of sodium nitrite.

Anti-oxidative and anti-inflammatory can be obtained from various types of plants, one of which is *Acorus calamus* L. It is a water plant that contains phytochemical compounds such as alkaloids, carbohydrates, flavonoids, tannins, and phenolics (Muchtarmah et al., 2019). With its content of phytochemical compounds, the ethanol extract of *A. calamus* L. rhizome can prevent the suppression of stressed rats' immune systems in normal rats. In addition, the administration of ethanol extract of *A. calamus* L. rhizome can affect the histology of the rat's spleen in the form of structural involution of lymphoid organs, and the administration of ethanol extract of *A. calamus* L. rhizome can reduce the area of white pulp damage in stressed rats compared to the control group (Sarjan et al., 2017). There is a little information about the potential of *A. calamus* L. rhizome in repairing damage to the structure of the spleen, so we examined the influence of ethanol extract of *A. calamus* L. rhizome in improving the spleen structure of white rats in histology-induced sodium nitrite (NaNO_2).

MATERIALS AND METHODS

Preparation of *A. calamus* L. extract

Acorus calamus L. rhizome that was used in this research was obtained from Pematang Siantar, North Sumatra. *A. calamus* L. rhizome was cut into small pieces and then dried by air for 4-5 days. Dried using a blender until it becomes a simplicia powder (powder derived from *A. calamus* L.). After

that, extraction of rhizome powder was carried out by using the maceration method with 96% ethanol in a ratio of 1:10. A total of 800 g of the rhizome powder was added to 8000 ml of 96% ethanol. The extraction process was done for three consecutive days at Universitas Islam Negeri Sumatera Utara Laboratory. The obtained filtrate was concentrated by a rotary evaporator for 4 days at a temperature of 40-50°C.

Experimental design

This was an experimental study using a completely randomized design. A total of 25 male rats (*Rattus norvegicus* L. strain Galur Wistar) aged 3-4 months with weights ranging from 129-176 grams. The rats used were obtained from the Pharmacology Laboratory of Medan, North Sumatra. The rats were acclimatized for seven days by feeding and drinking according to laboratory standards for experimental animals. The use of experimental animals was approved by the Animal Research Ethics Committee of the faculty of mathematics and natural science, Universitas Sumatera Utara (No. 0424/KEPH-FMIPA/2021) on July 14th, 2021.

Experimental animals were divided into five groups ($n=5$). The negative control group (NC) was given 0.5% carboxy methyl cellulose (CMC) for 40 days 0.5% CMC was used as an extract solvent, in the negative control group 0.5% CMC was used as a comparison test preparation because 0.5% CMC does not cause harm to the rat's body (Baran et al. 2020). 0.5% CMC test preparation, extract, and sodium nitrite were used as daily administration (made as stock solution), where 1 cc of test preparation (sodium nitrite (50mg/kg BW), 0.5% CMC and extract (250 mg/kg BW, 500 mg/kg BW and 750 mg/kg BW)) for 100 g rats. The administration of test preparations was carried out orally, from the roof of the oral cavity to the stomach. Sodium nitrite administration was carried out in the morning (PC, T1, T2, and T3), extract administration (T1, T2 and T3) and 0.5% CMC (NC and PC) in the afternoon. CMC 0.5%. The positive control group (PC) was given NaNO_2 for days 1-15, NaNO_2 and 0.5% CMC for days 16-30, and 0.5% CMC for days 31-40. Treatment group 1 (T1), treatment group 2 (T2), and treatment group 3 (T3) were given NaNO_2 for days 1-15. For days 16-30, a combination of NaNO_2 and *A. calamus* L. rhizome ethanolic extract was given. A 50 mg/kg BW NaNO_2 solution was used at a dose of 50 mg/kg BW. *A. calamus* L. rhizome ethanolic extract at

doses of 250 mg/kg BW, 500 mg/Kg BW, and 750 mg/kg BW for T1, T2, and T3 were given, respectively. For days 31-40, T1, T2, and T3 groups were given extracts at doses of 250mg/kg BW, 500 mg/kg BW, and 750 mg/kg B W. The volume of sodium nitrite solution given was adjusted to the daily weight of the rat. After treatment for 40 days, the rats were dissected on day 41, before that, the rats were satisfied for 14 hours. Furthermore, 5 rats in each group were euthanized by inhalation of ether ($\pm 0,67$ ml/animal) for 60 seconds.

Spleen macroscopic study

The spleen was cleaned using 0.9% NaCl prior to macroscopic observations that included examination of the weight, length, and width of the spleen. The observation of the length and width of the spleen organ was done using the bar in cm units. While the relative organ weight determination was computed using the formula:

$$\text{Relative organ weight} = \frac{\text{organ weight}}{\text{body weight}} \times 100$$

Spleen histology study

Cleaned spleen was fixed using 10% neutral buffered formalin. The spleens that have been cleaned are then fixated using Neutral Buffered Formalin at 10%. After that, the spleen was made into a histology slide using the paraffin method with hematoxylin-eosin staining (Afiqoh et al. 2017). The histology slide was observed under a light microscope with a magnification of 10X to measure the white pulp area and 40X magnification to observe bleeding lesions in lymphoid tissue, then scored with the scoring method (focal bleeding is 1, multifocal bleeding is 2, and diffuse bleeding (heavy

bleeding) is 3) (Hidayati et al., 2018). The white pulp area in each sample was measured using Image J software on a scale of 100 mm.

Statistical analysis

The results of scoring bleeding lesions and these morphometry measurements of the white pulp area were analyzed with one-way ANOVA using the SPSS (Statistical Product and Service Solutions) program 26. If there is a noticeable change ($P < 0.05$), the Duncan test was used to determine the difference in the dose given. In addition, observations of the histological structure were also carried out by comparing the control with each treatment that will then be described.

RESULTS AND DISCUSSION

Spleen macroscopic

The results of the average value of the weight, length, and width of the spleen show that the NC and PC groups have the same average value of weight and width, but the average value of the spleen length of the NC group is greater than the PC group. Control groups (NC and PC) had a lower average spleen weight, length, and width than the treatment groups (T1, T2, and T3). The T1 group had an average spleen length and width greater than the T2 and T3 groups. The T3 group had an average value of spleen weight greater than T1 and T2. The T2 group had an average value of weight, length, and width smaller than the T1 and T3 groups. The largest spleen length, and width are found in the T1 group while the smallest spleen length and width are in the T2 group. The largest spleen weight is found in T3 while the smallest spleen weight is in the T2 group (Table 1).

Table 1 Average change in weight, length, and width of the spleen

Group	Spleen Weight (g) (Average \pm SD)	P- Value (Anova)	Spleen Length (cm) (Average \pm SD)	P-Value (Anova)	Spleen Width (cm) (Average \pm SD)	P-Value (Anova)
NC	0.29 \pm 0.02 _a	<0.001	3.28 \pm 0.13 _{ab}	<0.001	0.78 \pm 0.08 _a	0.016
PC	0.29 \pm 0.04 _a		3.12 \pm 0.21 _a		0.78 \pm 0.10 _a	
T1	0.46 \pm 0.10 _b		4.02 \pm 0.21 _d		1.04 \pm 0.13 _b	
T2	0.30 \pm 0.06 _a		3.48 \pm 0.33 _{bc}		0.88 \pm 0.13 _{ab}	
T3	0.53 \pm 0.12 _b		3.64 \pm 0.32 _c		0.96 \pm 0.16 _{ab}	

* SD: Standard deviation. a, b, c dan d letters (Duncan test). NC: induced CMC 0.5% for 40 days, PC: induced NaNO₂ sub-acute dose (50 mg/kg BW) for 30 days + CMC 0,5% for 25 days, T1: induced NaNO₂ sub-acute dose (50 mg/kg BW) for 30 days + ethanol extract of *A. calamus* L. with dose 250 mg/kg BW for 25 days, T2: induced NaNO₂ sub-acute dose (50 mg/kg BW) for 30 days + ethanol extract of *A. calamus* L. with dose 500 mg/kg BW for 25 days, T3: induced NaNO₂ sub-acute dose (50 mg/kg BW) for 30 days + ethanol extract of *A. calamus* L. with dose 750 mg/kg BW for 25 days

Spleen histology

Histology observation of lymphoid tissue includes two examinations: bleeding lesions and measurement of the white pulp area. The results of the examination of bleeding lesions in lymphoid tissue showed that the administration of an ethanol extract of *A. calamus* L. rhizome had no noticeable effect on bleeding lesions in the entire treatment group ($P < 0.05$). From the observations, bleeding lesions occurred in all experimental groups with the same category of pathology levels (multifocal bleeding) between the NC, PC, T1, T2, and T3 groups (Table 2 and Figure 1). This showed that the ethanol extract of *A. calamus* L. rhizome did not make a significant difference to the bleeding lesions of the rat's spleen induced with sodium nitrite.

The results of the examination of the white pulp area showed noticeable difference ($P < 0.05$). Where white pulp area of NC, PC, T1 and T2 had the same amount of white pulp area but are different from T3 (Table 3 and Figure 2). This showed that the ethanol extract of *A. calamus* L. rhizome made a difference to the average value of the white pulp of the rat's spleen area induced with sodium nitrite at a dose of 750 mg/kg BW.

The result showed that the administration of an ethanol extract of *A. calamus* L. rhizome to the rat spleen induced with sodium nitrite caused a change in the average size of the weight, length, and width of the spleen in the entire treatment group (Table. 1). There were significant differences in the size of weight, length, and width of the spleen between the control group and the treatment group. The largest spleen length and width category is found in the T1 group (dose of 250 mg/kg BW) while the smallest is found in the T2 group (500 mg/kg BW). The largest spleen weight category is in the T3 (750 mg/kg BW) group while the smallest is in the T2 group (500 mg/kg BW). The weight and length of the spleen are closer to those

of the negative control group, were the T2 group (500 mg/kg BW). While the length of spleen of doses of 250 and 750 mg/kg BW are closer to the negative control group. This shows that the administration of *A. calamus* L. ethanolic extract at a dose of 500 mg/kg BW has an influence on repairing damage to the spleen weight and length. While doses of 250 mg/kg BW and 750 mg/kg BW in the T1 and T3 groups had an improving effect on the length of the spleen when compared to other groups. Differences in spleen weight variations can occur due to differences in the size of the body weight of rats used. In addition, previous studies have shown that giving herbal extracts in high doses can increase spleen weight (Hidayah et al. 2022). The growing size of the rats affects the number and size of cells in the spleen. Although there was an increase in the weight and width of the spleen in the T1 and T3 groups, the weight of the spleen was still included in the normal category of 0.09-1.68 g for rats euthanized using ether with bodyweight 20-400 g where the spleen did not swell (splenomegaly) (Webster 1947). In addition, the age of the rats also affects the spleen weight (Falconer et al. 1978). The length and width of the spleen follow the weight of the spleen.

Spleen exposed to immunogens causes an immune response in the spleen. If the immune activity increases, then the proliferation activity increases as well, so that the spleen tissue creates new red blood cells. Swelling of the spleen occurs due to macrophage cells present in the spleen tissue actively phagocytizing foreign substances. Changes in spleen weight are the result of the spleen's response to the presence of body immunity (Wahyuningsih et al., 2017). The immune response occurs because it is a form of interaction between one component and another component of the immune system.

Table 2 Average score of bleeding lesions

Group	Bleeding lesions (Average ± SD)	P-Value (Anova)
NC	1.88±0.48 ^a	0.334
PC	1.68±0.22 ^a	
T1	2.24±0.26 ^a	
T2	1.88±0.54 ^a	
T3	1.92±0.41 ^a	

*SD: Standard deviation. a letter (Duncan test). NC: induced CMC 0.5% for 40 days, PC: induced NaNO₂ sub-acute dose (50 mg/kg BW) for 30 days + CMC 0,5% for 25 days, T1: induced NaNO₂ sub-acute dose (50 mg/kg BW) for 30 days + ethanol extract of *A. calamus* L. with dose 250 mg/kg BW for 25 days, T2: induced NaNO₂ sub-acute dose (50 mg/kg BW) for 30 days + ethanol extract of *A. calamus* L. with dose 500 mg/kg BW for 25 days, T3: induced NaNO₂ sub-acute dose (50 mg/kg BW) for 30 days + ethanol extract of *A. calamus* L. with dose 750 mg/kg BW for 25 days. Significant value ($P < 0.05$)

Table 3 Average area of white pulp

Group	White pulp area (μm^2) (Average \pm SD)	P-Value (Anova)
NC	234888.96 \pm 18578.54 ^a	0.048
PC	217519.44 \pm 49263.50 ^a	
T1	234946.27 \pm 11079.39 ^a	
T2	231697.39 \pm 51656.59 ^a	
T3	285565.537 \pm 15528.73 ^b	

*SD: Standard deviation, a and b letters (Duncan Test) that show significant differences $P < 0.05$ (Anova). NC: induced CMC 0.5% for 40 days, PC: induced NaNO_2 sub-acute dose (50 mg/kg BW) for 30 days + CMC 0.5% for 25 days, T1: induced NaNO_2 sub-acute dose (50 mg/kg BW) for 30 days + ethanol extract of *A. calamus* L. with dose 250 mg/kg BW for 25 days, T2: induced NaNO_2 sub-acute dose (50 mg/kg BW) for 30 days + ethanol extract of *A. calamus* L. with dose 500 mg/kg BW for 25 days, T3: induced NaNO_2 sub-acute dose (50 mg/kg BW) for 30 days + ethanol extract of *A. calamus* L. with dose 750 mg/kg BW for 25 days

From the results of a macroscopic observations of the spleen, it can be concluded that the administration of ethanol extract of *A. calamus* L. the rhizome does not influence the weight, length, or width of the rat's spleen induced with sodium nitrite. In addition, the biotransformation activity of sodium nitrite does not occur directly in the spleen. Spleen exposed to toxicity agents can cause changes in the anatomical structure of the spleen (Cesta, 2006). However, in this case, no changes in anatomical structure were found from the observation of the weight, length, and width of the rat spleen. Therefore, it is necessary to make microscopic observations to find out the effect of giving sodium nitrite and ethanol extracts of *A. calamus* L. rhizomes on the rat's spleen. Further observations carried out are tissue checks including bleeding lesions and measurements of the white pulp area of the spleen.

On observation of bleeding lesions in lymphoid tissue, no difference was found (Table 2). In this study, there was bleeding in the entire treatment group. This happened because the spleen serves itself as a place of blood cell formation as well as a place of destruction of blood cells that have been damaged and is tasked with removing unneeded substances in the body. In addition, bleeding in lymphoid tissue can occur due to chemical exposure (Ward et al., 1999) including sodium nitrite, and trauma (Hidayati et al., 2018). The presence of nitrites in the body can cause blood pressure to be low due to a lack of erythrocyte and hemoglobin levels, causing the depletion of hemoglobin's ability to transport oxygen. The presence of nitrites in the human body can result in a hemoglobin change into methemoglobinemia (Durão et al., 2020). The high content of methemoglobinemia in the body can cause tissue hypoxia. Tissue hypoxia can cause oxidative stress and produce free radicals, resulting

in bleeding. Discharge in lymphoid tissue can also occur if the rats used are subjected to physical trauma, such as injury. Bleeding in lymphoid tissue is included in one form of immune response carried out by the spleen (Petroni et al., 2017).

The results of the white pulp's average area, necrosis can be seen from the shrinkage of the area or diameter of the white pulp (Suttie, 2006). Administration of sodium nitrite leads to focal necrosis and shrinkage of lymphoid tissue. Table 3 showed that the PC group given sodium nitrite for 30 days experienced a greater shrinkage of the white pulp area than the NC group.

This shrinkage of the white pulp area may be due to the presence of the sodium nitrite effect. Sodium nitrite can cause the accumulation of lipid peroxidase in lymphocyte cells. Lipid peroxidase will affect membrane crosslinking, membrane fluidity, as well as membrane structure and function. This is what causes necrosis of lymphocyte cells which reduces the number of lymphocyte cells and shrinks the white pulp area (Mohammed, 2014; Amin et al., 2016).

The results of the white pulp average area show that the group with ethanol extract of *A. calamus* L. rhizome at doses of 250 and 500 mg/kg BW is closer to the white pulp area of the NC group (Table 3), where the antioxidant activity of *A. calamus* L. rhizome is in the dose range of 250-500 mg/kg BW (Palani et al., 2010; Sindelar & Milkowski 2012). This may be due to the presence of secondary metabolites in the ethanol extract of *A. calamus* L. rhizomes such as flavonoids, tannins, and alkaloids (Mughtaromah et al., 2017) that are known to have antioxidant activity with an IC_{50} value based on Barua et al., 2014 study that is IC_{50} 54.82 (DPPH radical scavenging activity), IC_{50} 118.802 (nitric oxide scavenging activity), IC_{50} 109.45

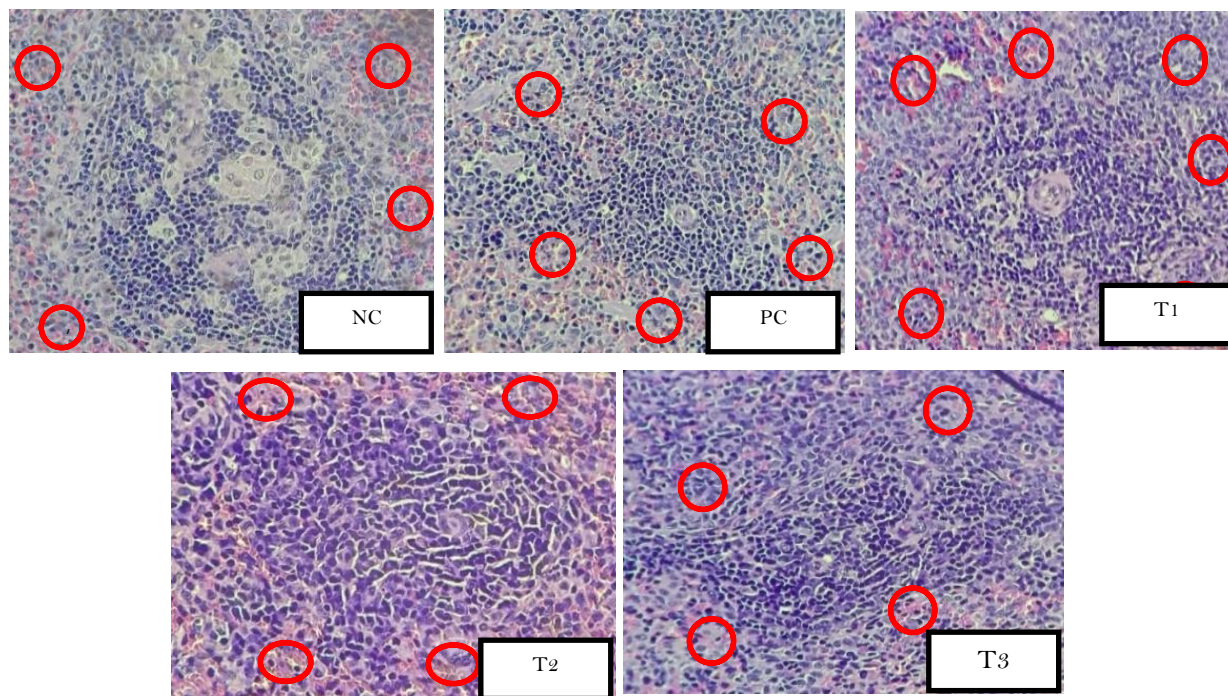


Figure 1. Spleen bleeding lesions. NC: induced CMC 0.5% for 40 days, PC: induced NaNO₂ sub-acute dose (50 mg/kg BW) for 30 days + CMC 0,5% for 25 days, T1: induced NaNO₂ sub-acute dose (50 mg/kg BW) for 30 days + ethanol extract of *A. calamus* L. with dose 250 mg/kg BW for 25 days, T2: induced NaNO₂ sub-acute dose (50 mg/kg BW) for 30 days + ethanol extract of *A. calamus* L. with dose 500 mg/kg BW for 25 days, T3: induced NaNO₂ sub-acute dose (50 mg/kg BW) for 30 days + ethanol extract of *A. calamus* L. with dose 750 mg/kg BW for 25 days. Multifocal bleeding (red circle). H&E; 40X

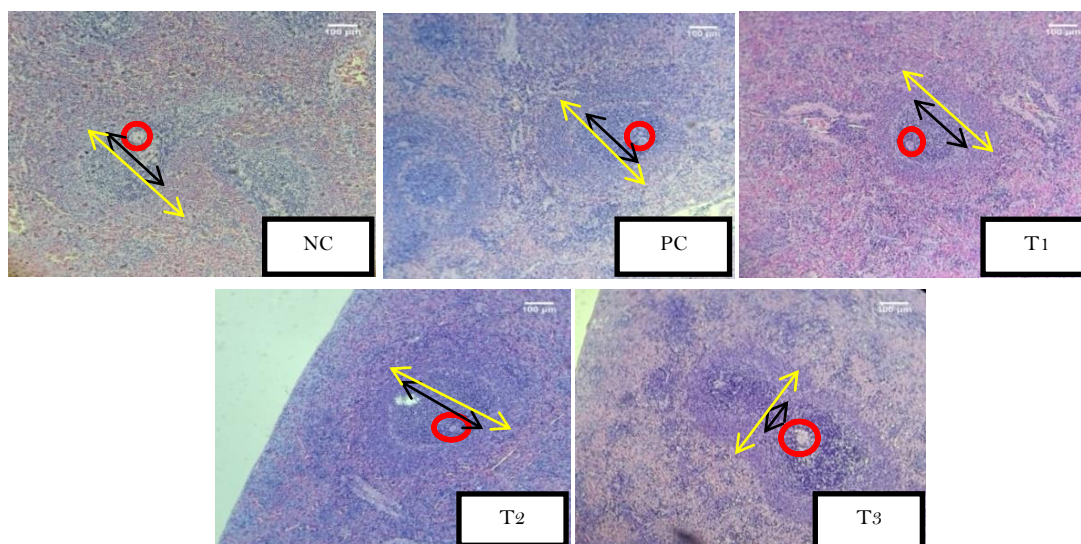


Figure 2. The spleen histology results in a different group. NC: induced CMC 0.5% for 40 days, PC: induced NaNO₂ sub-acute dose (50 mg/kg BW) for 30 days + CMC 0,5% for 25 days, T1: induced NaNO₂ sub-acute dose (50 mg/kg BW) for 30 days + ethanol extract of *A. calamus* L. with dose 250 mg/kg BW for 25 days, T2: induced NaNO₂ sub-acute dose (50 mg/kg BW) for 30 days + ethanol extract of *A. calamus* L. with dose 500 mg/kg BW for 25 days, T3: induced NaNO₂ sub-acute dose (50 mg/kg BW) for 30 days + ethanol extract of *A. calamus* L. with dose 750 mg/kg BW for 25 days. White pulp (yellow arrow), central artery (red circle), germinal center (black arrow), H&E. (Scale bar 100 μm; 40X) hydroxyl radical (scavenging activity) and IC₅₀ 38.3 (superoxide radical scavenging activity). with flavonoid levels in an extract of *A. calamus* L. rhizome of 5.30 mg Quercetin Equivalent (QE)/g (Rawat et al., 2016). Flavonoids have the function of maintaining cell structure by stopping reactions from free radicals mediated by cytotoxicity and lipid peroxidation, as well as stabilizing free radicals (Datta et al. 2004).

In the T3 group, the average white pulp area is much larger and different than in other groups. This can occur due to the toxic effect of ethanol extract of *A. calamus* L. rhizome at a dose of 750 mg/kg BW it causes hyperplasia of lymphocyte cells in the white pulp (Figure. 2). Lymphocyte hyperplasia in white pulp is an increase in the number of polyclonal lymphocytes (Suttie, 2006). Hyperplasia is a form of immune response carried out by cells to antigens in the body (Kumar et al., 2012). Hyperplasia is closely related to the vacuolization of red pulp cells (Anwar et al., 2018) but it is not explained exactly what the correlation is. A Study conducted by (Shah et al. 2012) showed that the safe dosage of ethanol extract of *A. calamus* L. was 600 mg/kg BW. The administration of ethanol extract of *A. calamus* L. rhizome at a dose of 800 mg/kg BW vacuolization occurred in the red pulp of the spleen (Nath et al., 2017).

This is thought to be the cause of the expansion of the white pulp region in the T3 group. White pulp hyperplasia and red pulp vacuolization in the spleen may occur due to the high dose of ethanol extract of *A. calamus* L. rhizome that caused an increase in the white pulp area. The effect of these toxic substances can occur when there is a biochemical interaction between the toxic substances in the extract and the cells in the white pulp. Chemical compounds are toxic when given in excessive doses. One of the compounds that is potentially toxic from ethanol extract of *A. calamus* L. rhizome is β -asarone. The essential oil of *A. calamus* L. contains several phytochemical compounds (up to 96%) as the phenolic ether "asaron". There are three forms of asarone, including α -asarone, β -asarone, and γ -asarone.

One of the forms of asarone that is likely to have the worst impact on health is β -asarone. β -asarone is a pro-carcinogenic compound whose use has been prohibited by CEFS (Council of European Committee on Food and Flavoring) (Mittal et al. 2015) and the FDA (Food and Drug Administration) because it has potential carcinogenic effects, which is delivered from triploid and tetraploid strains, while *A. calamus* L. plants are low in β -asarone content, delivered from diploid and hexaploid strains (Sharma et al. 2020). Toxicology studies show that β -asarone caused hepatocellular carcinoma, mutagenic, genotoxic, and teratogenic effects on animal models (Matin et al., 2022; Zhang I., 2022). Because of its toxic effect, it is suspected that tannin and β -asarone compounds present in the extract with the highest

concentration (750 mg/kg BW) cause the expansion of the white pulp region in the T3 group. Ecological, geographical location, and seasonal variation are some of the factors that affect the large content of asaron compounds (Mittal 2015).

CONCLUSION

The administration of ethanol extract of *A. calamus* L. rhizome affects the weight, length, and width of the spleen ($P < 0.05$) but the size of the organ is still in the normal category. On histological observation, administration of *A. calamus* L. rhizome ethanolic extract did not affect the bleeding lesions of the lymphoid tissue but had a noticeable effect on the white pulp area of the rat spleen induced with sodium nitrite ($P < 0.05$). A dose of 250 mg/kg BW *A. calamus* L. rhizome ethanolic extract has an impact on improving the size of the spleen weight and width length; dose of 500 mg/kg BW has an impact on improving the size of the spleen weight and length; and a dose 750 mg/kg BW has an impact on improving spleen width length. While doses of 250 and 500 mg/kg BW rhizome extract repair lymphoid tissue.

ACKNOWLEDGMENT

The authors would like to thank the Faculty of Science and Technology, Universitas Islam Negeri Sumatera Utara Medan for the facility support of the Biology Laboratory. We also thank the head of the biology program study department of Universitas Islam Negeri Sumatera Utara Medan, who provided good cooperation in this research. And last, we also thank Russell Ong, M.S. who helped in the correction process.

REFERENCES

- Afiqoh AN, Fidianingsih I, Handayani ES. (2017). Pengaruh Pemberian Ekstrak Etanol Daun Pegagan (*Centella asiatica*) terhadap Gambaran Histopatologi Limpa Tikus (*Rattus norvegicus*) yang diinduksi Sodium Nitrit Sub Akut. *JK Unila*, 1, 457–462. <https://doi.org/10.23960/jkunila13457-462>
- Amin RA, Elsabagh RA, Amin A. (2016). Protective Effects of Ascorbic Acid and Garlic Oil against Toxic Effects Induced by Sodium Nitrite as Meat Additive in Male Rats. *16(6)*, 508–524. <https://doi.org/10.5829/idosi.gv.2016.16.06.10393>
- Baran A, Sulukan E, Türkoğlu M, Ghosigharehagaji A, Yildirim S, Kankaynar M, Bolat I, Kaya M, Topal A, Ceyhun SB. (2020). Is sodium carboxymethyl cellulose (CMC) really completely innocent? It may be triggering obesity. *Int J Biol Macromol*, 163, 2465–2473. <https://doi.org/10.1016/j.ijbiomac.2020.09.169>
- Brake DA, Fedor CH, Werner BW, Miller TJ, Taylor RL, Clare RA. (1997). Characterization of immune response to *Eimeria tenella* antigens in a natural immunity model

- with hosts which differ serologically at the B locus of the major histocompatibility complex. *Infect Immun*, 65(4), 1204–1210. <https://doi.org/10.1128/iai.65.4.1204-1210.1997>
- Cesta MF. (2006). Toxicologic Pathology. <https://doi.org/10.1080/01926230600867743>
- Datta N, Singanusong R, Chen SS, Yao LH, Jiang YM, Shi J, As-barber FATOM. 2004. *Flavonoids in Food and Their Health Benefits*, 113–122.
- Durão C, Pedrosa F, Dinis-Oliveira RJ. (2020). A fatal case by a suicide kit containing sodium nitrite ordered on the internet. *J Forensic Leg Med*. 73:10–13. <https://doi.org/10.1016/j.jflm.2020.101989>
- Falconer BYDS, Gauld IK, Roberts RC. (1978). Cell numbers and cell sizes in organs of mice selected for large and small body size. :287–301.
- Hidayah N, Rahmawati I, Amelia J, Prakoso YA. 2022. Pengaruh ekstrak teh kombucha (*Medusomyces gisevii*) terhadap berat dan histopatologis limpa tikus wistar (*Rattus norvegicus*) yang diinfeksi *Escherichia coli*. *VITEK Bid Kedokt Hewan*. 12(1):26–34. <https://doi.org/10.30742/jv.v12i1.97>
- Hidayati E, Berata IK, Samsuri S, Sudimartini LM, Merdana IM. (2018). Gambaran Histopatologi Limpa Tikus Putih yang Diberi Deksametason dan Vitamin E. *Bul Vet Udayana*. 10(1):18. <https://doi.org/10.24843/bulvet.2018.v10.i01.p03>
- Hoffbrand, A. V., Pettit, J. E., Moss PAH. 2001. *Essential Haematology (Essentials)*. Fourth Edi. Oxford: Wiley-Blackwell.
- Juibar, F., Kazerooni, A. T., and Ranjbar AG. (2015). Histopathological effects of sodium nitrite on the spleen of male and female rats. *Iran South Med J*, 17(6), 1160–1167. <http://ismj.bpums.ac.ir/article-1-632-en.html>
- Karwowska M, Stadnik J, Wójciak K. (2021). The effect of different levels of sodium nitrate on the physicochemical parameters and nutritional value of traditionally produced fermented loins. *Appl Science*, 11(7). <https://doi.org/10.3390/app11072983>
- Kumar, V., Abbas, A., Aster J. (2012). *Robbins Basic Pathology*. Philadelphia, PA: Elsevier.
- Ma L, Hu L, Feng X, Wang S. (2018). Nitrate and nitrite in health and disease. *Aging Dis*, 9(5),938–945. <https://doi.org/10.14336/AD.2017.1207>
- Matin AM, Boie ET, Moore GP. (2022). Survival after self-poisoning with sodium nitrite: A case report. *J Am Coll Emerg Physicians Open*, 3(2):4–7. <https://doi.org/10.1002/emp2.12702>
- Mittal N, Varshney VK SB and GH. 2015. High Levels of Diversity in the Phytochemistry, Ploidy and Genetics of the Medicinal Plant *Acorus calamus* L. *Med Aromat Plants*. <https://doi.org/10.4172/2167-0412.S1-002>
- Mohammed FF. (2014). Effect of Marjoram Oil on the Clinicopathological, Cytogenetic and Histopathological Alterations Induced by Sodium Nitrite Toxicity in Rats. *Glob Vet*.(January). <https://doi.org/10.5829/idosi.gv.2014.12.05.83186>
- Muchtaromah B, Ahmad M, S EK, A YM, A VL. (2017). Phytochemicals, Antioxidant and Antifungal Properties of *Acorus calamus*, *Curcuma mangga*, and *Allium sativum*. *KnE Life Science*, 3(6), 93. <https://doi.org/10.18502/kl.v3i6.1119>
- Muchtaromah B, Hayati A, Agustina E. (2019). Phytochemical Screening and Antibacterial Activity of *Acorus calamus* L. *Extracts*. 4: 68–78. <https://doi.org/10.15575/biodjati.v4i1.4235>
- Nanda, B. L., Sayeeda, N, S, G., and Thulasi, T R. (2014). Determination of Phytochemicals and Antioxidant Activity of *Acorus calamus* Rhizome. *J Drug Deliv Ther*. 4(6),117–121. <https://doi.org/https://doi.org/10.3390/antiox10071061>
- Nath P, Yadav AK, Soren AD. (2017). European Journal of Sub-acute Toxicity and Genotoxicity Assessment of The Rhizome Extract of *Acorus calamus* L. *A Medicinal Plant of India*, 4(08), 392–399.
- Palani, S., Raja, S., Kumar, R. P., Parameswaran, P., and Senthil K. (2010). Therapeutic efficacy of *Acorus calamus* on acetaminophen induced nephrotoxicity and oxidative stress in male albino rats. *Acta Pharm Sci*, 52, 89–100.
- Petrone P, Anduaga Peña MF, Servide Staffolani MJ, Brathwaite C, Axelrad A, Ceballos Esparragón J. 2017. Evolución en el tratamiento conservador del traumatismo esplénico contuso. *Cir Esp*, 95(8), 420–427. <https://doi.org/10.1016/j.ciresp.2017.07.007>
- Petrova E, Gluhcheva Y, Pavlova E, Vladov I, Voyslavov T, Ivanova J. (2020). Effect of acute sodium nitrite intoxication on some essential biometals in mouse spleen. *J Trace Elem Med Biol*, 58, 126431. <https://doi.org/10.1016/j.jtemb.2019.126431>
- Rawat S, Arun KJ, Amit B, Asutosh B, Indra DB, Ranbeer SR UD. (2016). Anti-oxidant and anti-microbial properties if some ethno-therapeutically important medicinal plants of Indian Himalayan Region. *Biotech*. 6(1),1–12. <https://doi.org/10.1007/s13205-016-0470-2>
- Sanjari, R., & Hosseini SE. (2021). Research Paper Effects of Perinatal and Neonatal Sodium Nitrite on Serum Levels of Uric Acid, Urea, Creatinine, and Tissue Structure of Rats' Offspring Kidneys. *Q Horiz Med Sci*. 27(2):214–228. <https://doi.org/https://doi.org/10.598/hms.27.2.1428.15>
- Sarjan HN, Divyashree S, Yajurvedi HN. (2017). The protective effect of the Vacha rhizome extract on chronic stress-induced immunodeficiency in rat. *Pharm Biol*. 55(1):1358–1367. <https://doi.org/10.1080/13880209.2017.1301495>
- Shah PD, Ghag M, Deshmukh PB, Kulkarni Y, Joshi S V. (2012). Toxicity study of ethanolic extract of *Acorus calamus* rhizome. *International Journal of Green Pharmacy*, 20(2),9–35. <https://doi.org/10.4103/0973-8258.97119>
- Sharma V, Sharma R, Gautam DS, Kuca K. (2020). Role of Vacha (*Acorus calamus* Linn .) in Neurological and Metabolic Disorders: Evidence from Ethnopharmacology , Phytochemistry , Pharmacology and Clinical Study. *J Clin Med*, 34(2), 1–45. <https://doi.org/10.3390/jcm9041176>
- Sindelar JJ, Milkowski AL. (2012). Human safety controversies surrounding nitrate and nitrite in the diet. Nitric Oxide - *Biol Chem*, 26(4), 259–266. <https://doi.org/10.1016/j.niox.2012.03.011>
- Stewart H. Webster EJL and DJZ. (1947). For liver, :447–513.
- Suparmi S, Fasitasari M, Martosupono M, Mangimbulude JC. (2016). Comparisons of Curative Effects of Chlorophyll from *Sauropus androgynus* (L) Merr Leaf Extract and Cu-Chlorophyllin on Sodium Nitrate-Induced Oxidative Stress in Rats. *J Toxicol*, 20(1),123–134. <https://doi.org/10.1155/2016/8515089>
- Suttie AW. (2006). Toxicologic Pathology. <https://doi.org/10.1080/01926230600867750>
- Turk R, Vnuk D, Svetina A, Flegar-meštrič Z. (2009). Anti-oxidative/anti-inflammatory paraoxonase activity and lipid alterations after total splenectomy and autologous spleen transplantation in pigs. *Veterinary Archives* 79(1):1–10.
- Wahyuningsih SPA, Pramudya M, Putri IP, Savira NII, Winarni D, Suhargo L, Darmanto W. (2017). Okra

- Polysaccharides Improves Spleen Weight and B-Lymphocytes Proliferation in Mice Infected by *Staphylococcus aureus*. *Biosaintifika*, 9(3), 460. <https://doi.org/10.15294/biosaintifika.v9i3.11284>
- Ward, J. M., Mann, P. C., Morishima, H., Frith CH. (1999). Thymus, Spleen, and Lymph Nodes. Vienna: Cache River Prss.
- Wójciak KM, Stasiak DM, Keska P. (2019). The influence of different levels of sodium nitrite on the safety, oxidative stability, and color of minced roasted beef. *Sustain*, 11(14), 1–16. <https://doi.org/10.3390/su11143795>
- Zhang T, Yuan Q, Chen X, Hu L. (2022). Preclinical evidence and possible mechanisms of β -asarone for rats and mice with Alzheimer's disease: A systematic review and meta-analysis. *Aging Dis*, 10(5): 1075–1093. <https://doi.org/10.3389/fphar.2022.956746>.